

Modern Trends in Prosthetic Implant Rehabilitation of Patients: Case Report with 5-Year Follow-Up

SUMMARY

Background/Aim: Implant treatment expands extensively the possibilities of prosthetic treatment, which provide benefits, bigger comfort as well as general improvement of the patient's life quality. In cases with no possibility of implantation, it is possible to improve conditions by using modern methods for bone tissue repair. One of factors important for the long-term success is proper oral hygiene, as well as raising awareness of its importance to patients. The aim of the paper is to present a patient rehabilitated with multiple implants and followed-up for a five-year period, and to point out the importance of raising patient's awareness and motivation in order to preserve the results of the treatment. **Case Report:** A 31-year-old patient was admitted to the oral surgery clinic for rehabilitation of a poor oral health status. After taking history, clinical examination and additional analysis, the following treatment plan was suggested: to remove impacted upper canines and to put an implant supported by fixed prosthesis in the upper jaw, to make two implants supported by bridges laterally and one dental supported by bridge in the inter-canine sector in the lower jaw. The treatment was carried out in several stages that involved extraction of residual roots and impacted teeth, augmentation of bone defects with bone substitutes and bio-absorbable membranes, placing implant, and prosthetic rehabilitation. By verbal communication with the patient, we pointed out the importance of proper oral hygiene and regular check-ups. The five year follow-up showed the absence of factors that could adversely affect the success of the treatment, and the patient was still highly motivated to maintain proper oral hygiene. **Conclusions:** It is possible to achieve predictable results in complex cases by using a multiphase prosthetic treatment supported by implants. Concerning a long-term success, motivation, proper information and patient's willingness to cooperate play an important role.

Key words: Dental Implants, Motivation, Quality of Life, Rehabilitation

Aleksandar Đorđević¹, Mirko Mikić²,
Jelena Stanišić¹, Filip Đorđević¹

¹ Faculty of Medicine University of Prishtina -
Kosovska Mitrovica, Serbia

² Medical Faculty Podgorica, Podgorica,
Montenegro

CASE REPORT (CR)

Balk J Dent Med, 2019;40-44

Introduction

Implant treatment extensively expands possibilities of prosthetic rehabilitation, which becomes more acceptable to the patient, unlike conventional prosthetics compensations that may be the cause of dissatisfaction, causing decline in quality of life¹. The patients' decision to accept suggestion of undergoing implant treatment is based on several factors, primarily on expectation of improving function and aesthetics, as well as financial

aspect. For many patients, prosthetic rehabilitation with implants presents a definite need and directly affects quality of life, patient satisfaction and psychological state of mind³. However, in some cases, due to the absence of anatomical and morphological conditions (vertical and horizontal dimensions of the alveolar ridge and the proximity of anatomical structures such as the maxillary sinus in the maxilla and the mandibular canal in the mandible) implant rehabilitation may be carried out only by use of some additional procedures that modern treatment methods ensure⁴. The concept of

guided bone regeneration, which involves the use of a bone substitutes and bio resorptive membranes, allows vertical and horizontal bone augmentation in combination with a different surgical approach⁵. Moreover, it is well ascertained that implantation into bone substituent is possible, and that implants do not behave differently from implants embedded in natural bone⁶.

Patient's expectations are high and, therefore, as fixed prosthetic rehabilitation offers several advantages over rehabilitation with any kind of mobile prosthetic appliances, it should be a treatment of choice whenever it is possible⁷. However, there are several problems with implant supported fixed prosthetic appliances, especially the presence of excess cement, which is difficult to be removed, or additional difficulties in maintaining adequate oral hygiene⁸, especially if possibility of self-cleaning is heavy. Therefore, patient education in maintaining oral hygiene is necessary for long-term success whenever an implant supported fixed prosthetics is planned⁹. If patient's cooperation and motivation is not present, a plan of rehabilitation should be focused on conventional methods¹⁰.

The aim of this paper is to present a patient rehabilitated with multiple implants and followed-up for a five-year period, and to point out the importance of raising patient's awareness and motivation in preserving the results of the treatment.

Case Report

Patient BG, 31 years old, came to the Clinic of Oral Surgery, Medical Faculty, University of Pristina with headquarters in Kosovska Mitrovica. Except wish to improve his oral health from the aspect of aesthetics and function, patient didn't have any local complaint. After further interviewing and examining the patient, an extremely unfavourable oral health status and high anxiety for dental treatment was found (after completing a questionnaire suggested by Humphries *et al.*¹¹). Verbal monitoring and motivational interviews have established willingness of the patient to cooperate, enabling further clinical examination and implementation of supplementary diagnostic procedures.

Clinical examination revealed a lack of several teeth in the upper jaw and the advanced caries with extensive destruction of hard dental tissues at the rest of upper teeth (Figure 1), with multiple periapical lesions and the presence of both impacted upper canines. In the lower jaw, several teeth were missing or being carious.

Several options of prosthetic rehabilitation were offered to the patient. One of the options was an implant-supported fixed circular bridge in the upper jaw, two implant-supported bridges in both lateral regions of the lower jaw, and one dental-supported bridge in the

inter-canine region. After presentation of the treatment plan, the detailed briefing of the patient took place. The complexity of the process and the durability of the multi-phase care were pointed out, as well as factors that are important for the success of the therapy and of the possible complications. Education also included the aspect of the importance of an adequate oral care hygiene maintenance in patients with implants. The need of coming to regular follow-ups, and responsibility of the patient in the prevention of possible complications due to non-compliance with the proposed measures.

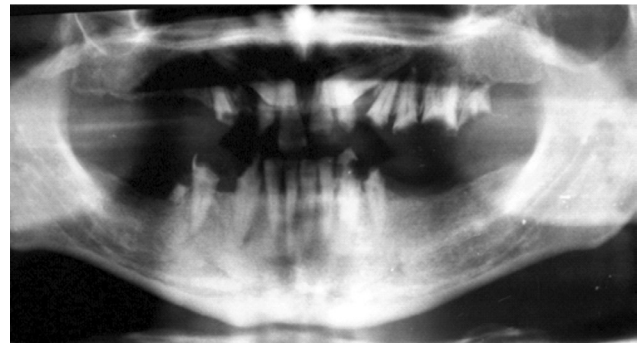


Figure 1. Panoramic radiograph before intervention

Preparation for Implantation

Multiple extractions of all teeth in the upper jaw took place in the first phase of patient rehabilitation. In the second phase, an endodontic-surgical treatment of lower frontal teeth was done, with simultaneous extraction of remaining lower teeth. The third stage involved surgical extraction of upper impacted canines with augmentation of bone defects in order to create favourable conditions for the implantation (Figure 2). Bone augmentation was performed by bone substitute (Bio-Oss[®]) and bio-resorptive membranes (Bio-Gide[®]). After a period of healing extraction wounds for six months and analysis of the CBCT image, the next stage encompassed the implant-prosthetic treatment.

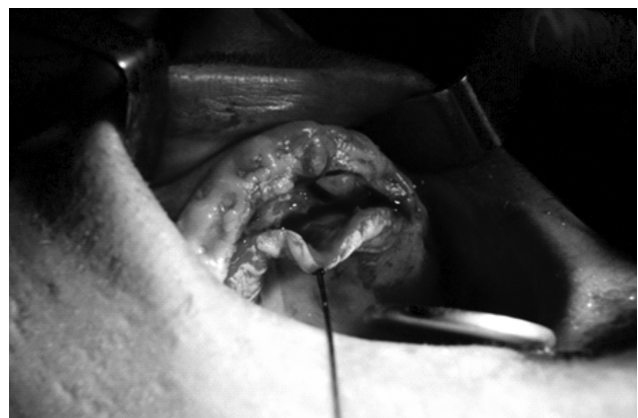

Figure 2. Surgical extraction of impacted canines

Surgical Aspect of Implant-Prosthetic Treatment

A two-phase surgical protocol of implantation comprised implantation and covering the implant in the first phase. Three Bredent “Blue Sky” implants were installed at the right side of the maxilla in the region of teeth #13, #14, and #15, with dimensions 4.0 x 12mm, 4.0 x 12mm, and 3.5 x 12mm, while at the left side, three implants of the same dimensions were put in the region of teeth #24, #25 and #26.

In the lower jaw, on the left side, we installed two implants in the region of teeth #34 and #35 (Bredent Blue Sky, dimensions 3.5x12 and 4.0x10). On the right side, in the region of teeth #43 and #45, we also installed two implants (3.5x10 and 4.0x10). In the prosthetic phase, this arrangement would allow a production of two lateral implant-supported bridges and a dentally supported bridge in the inter-canine sector.

After a three-month period of osseointegration (meanwhile, the patient worn a mobile prosthetic device), a second surgical phase was carried out, which comprised detection of implants and setting of gingival-formers for a period of another two weeks to form a proper gingival profile.

Prosthetic Aspect of the Treatment

Firstly, a single-phase print was taken and implant transfers placed, which were spliced to increase the stability and accuracy during the printouts (Figure 3). A re-registration of vertical relations was also performed due to the loss of the vertical dimension of occlusion. After that, a laboratory phase of the metal construction followed and after clinical testing, the laboratory phase was finished by placing ceramics. For a period of one month, the patient was wearing temporarily cemented compensation in order to make any corrections that might reconcile to expectations of the patient concerning to colour, shape, size and other characteristics of the prosthesis. Definitive cementation of bridges was performed by glass-ionomer cement (Figure 4).

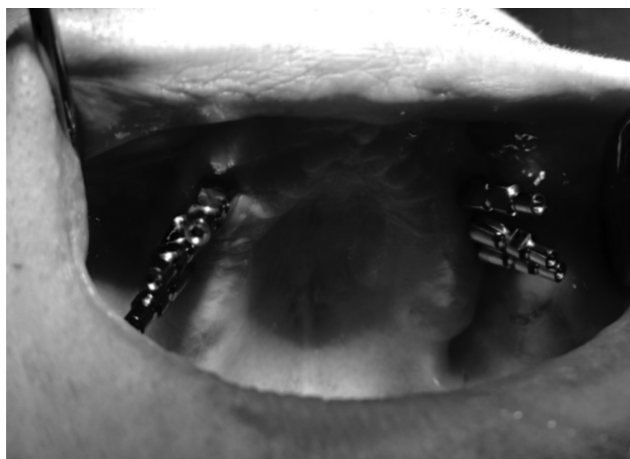


Figure 3. Transfers are placed on the implants

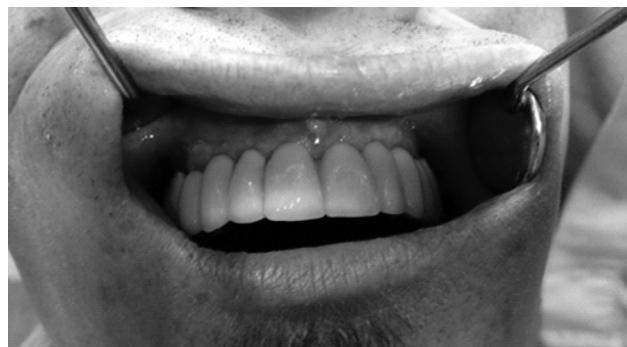

Figure 4. Definitively cemented prosthetic work

Maintaining Oral Hygiene

Measures related to the maintenance of oral hygiene were focused on mechanical and chemical control of dental plaque and food residues accumulation. The proposed methods of mechanical control included the use of soft toothbrushes, less abrasive tooth paste, interdental brushes and stimulants (“soft pick”), and an interdental aids adapted for patients with implants (“Superfloss”). Also, the patient was proposed to mechanically remove food residues by using water irrigation (“Water-pick” machine). For chemical control of dental plaque accumulation, non-alcoholic mouthwashes (0.12% chlorhexidine gluconate) were proposed, two to three times per day for a period of one month with pauses to avoid negative effects of the solution.

Follow-ups

At the follow-up six months after the submission of definitive prosthetic work, it was visible that the patient adhered to advices related to the maintenance of oral hygiene, and that the functionality and aesthetics were favourable, further motivating the patient to maintain a long-term advantageous result.

At the follow-up after one year, the gingiva did not show visual signs of inflammation. A plaque accumulation around implants was under control; clinical probing of the sulcus depth did not show noticeable resorption of bone tissue around the implants, and there was no bleeding on probing. By checking the occlusion, it was found that the occlusion was balanced, without traumatic contacts. Panoramic radiograms did not show signs of resorption of the peri-implant bone. The patient was satisfied with the result and expressed a high degree of motivation for further maintaining oral hygiene.

Five years after the treatment, everything was satisfactory (Figure 5). Further education on maintaining oral hygiene of the patient was not necessary since he adhered to everything that was proposed in the previous period. An analysis of panoramic radiogram revealed an absence of pathological bone resorption around implants (Figure 6).

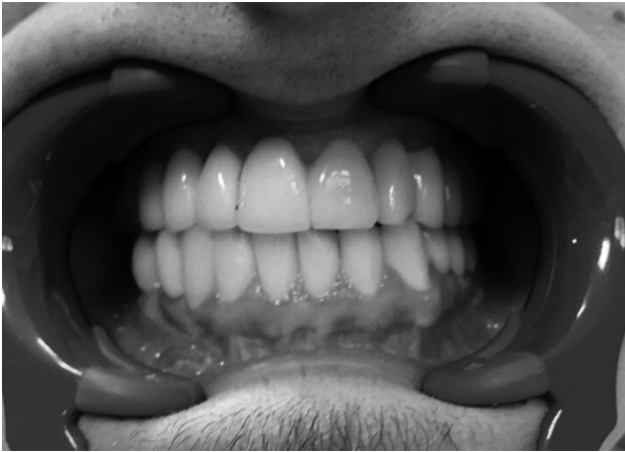

Figure 5. Clinical situation after 5 years

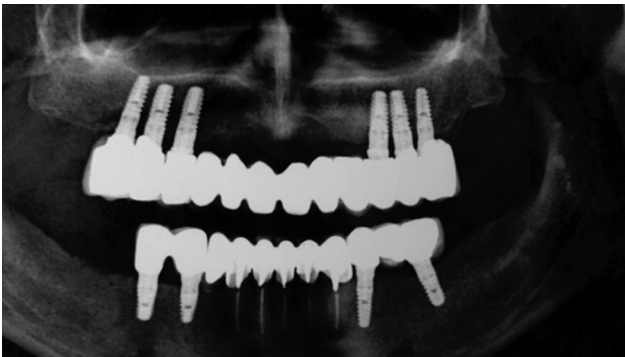

Figure 6. Panoramic radiography after 5 years

Discussion

There are several factors that may be the cause of an unfavourable oral health status expressed in toothless young people, one of which being fear of pain during dental treatment¹². Therefore, obtaining patient confidence at the beginning of treatment is essential¹³. Concerning our patient, an individual approach included primary education of the patient about the general causes of fear of dental interventions and informing him of modern methods of pain control. Applying potent local anaesthetics allows painless oral surgery, which is an important factor in gaining confidence of the patient, controlling fear from dental interventions, and achieving further motivation for continuing therapy¹⁴.

A modern approach in oral implantology implies a multidisciplinary approach in the treatment of complex cases and teamwork. Therefore, this patient was treated from psychological, surgical and prosthetic approaches. The surgical aspect of the presented patient encompassed some routine procedures, such as tooth apicoectomies in the lower frontal region or extraction of the impacted upper canines, but also some relatively modern methods, like the use of targeted bone regeneration protocol to

preserve and augment the residual alveolar ridge by bone substitutes in combination with membranes⁴, as bone defect was limited by bone tissue; in the case of major defects a solid non-corrosive membranes commonly made of titanium might be used to prevent deformation of the alveolar ridge¹⁵. Studies have shown that implantation into augmented bone can give predictive results as implantation into natural bone, depending on bone region and density¹⁶⁻¹⁸. Although several studies stressed a need for additional research, it seems that the use of bone substitutes in combination with bio-resorptive membranes can serve as an alternative to conventional protocols of implant insertion¹⁹⁻²¹.

Several studies have also shown the importance of interlinking implants with fixed prosthetic works because due to the mode of force distribution behaves as a unique functional unit^{22, 23}.

Concerning rehabilitation with implant supported fixed prostheses, in addition to fulfilling local clinical conditions needed for a long-term favourable result, a proper cooperation of the patient is absolutely necessary, as well as motivation and raising awareness of the importance of maintaining oral hygiene. Several authors state that the prevention of late complications in the form of peri-implant mucositis and periimplantitis but also the prevention of pathological resorption of peri-implant bone tissue is the matter of respecting biomechanical principles, balancing occlusal forces and maintaining adequate oral hygiene^{24,25}. The fact that cemented fixed prosthesis on implants cannot be removed during professional office maintenance, the maintenance of oral hygiene is a priority and a very important segment of preserving the health of peri-implant tissue^{26, 27}. Therefore, more attention have been paid to the patient's education concerning dental plaque accumulation, influence of pathogenic agents from bio film on peri-implant tissue, complications that can arise due to failure to maintain adequate oral hygiene, and the way in which the formation of deposits can be controlled.

Conclusions

It is possible to achieve predictable results in complex cases by using a multiphase prosthetic treatment supported by implants. Concerning a long-term success, motivation, proper information and patient's willingness to cooperate play an important role.

References

1. Blomberg S, Lindquist LW. Psychological reactions to edentulousness and treatment with jawbone-anchored bridges. Acta Psychiatr Scand, 1983;68:251-262.

2. Simensen AN, Bøe OE. Patient Knowledge and Expectations Prior to Receiving Implant-Supported Restorations. *Int J Oral Maxillofac Implants*, 2015;30:41-47.
 3. Buch RS, Weibrich G, Wegener J, Wagner W. Patient satisfaction with dental implants. *Mund Kiefer Gesichtschir*, 2002;6:433-436.
 4. Benic GI, Hammerle CH. Horizontal bone augmentation by means of guided bone regeneration. *Periodontol*, 2000 2014;66:13-40.
 5. Zitzmann NU, Schärer P, Marinello CP. Long-term results of implants treated with guided bone regeneration: A 5-year prospective study. *Int J Oral Maxillofac Implants*, 2001;16:355-366.
 6. Jung RE, Fenner N, Hammerle CH, Zitzmann NU. Long term outcome of implants placed with guided bone regeneration (GBR) using resorbable and non-resorbable membranes after 12-14 years. *Clin Oral Implants Res*, 2013;24:1065-1073.
 7. Jung RE, Pjetursson BE, Glauser R, Zembic A, Zwahlen M, Lang NP. A systematic review of the 5-year survival and complication rates of implant-supported single crowns. *Clin Oral Implants Res*, 2008;19:119-130.
 8. Chee W, Felton DA, Johnson PF, Sullivan DY. Cemented versus screw-retained implant prostheses: which is better? *Int J Oral Maxillofac Implants*, 1999;14:137-141.
 9. Augthun M, Tinschert J, Huber A. In vitro studies on the effect of cleaning methods on different implant surfaces. *J Periodontol*, 1998;69:857-864.
 10. Lekholm U, Zarb GA. Patient selection and preparation. In: Brånemark P-I, Zarb GA, Albrektsson T (editors). *Tissue integrated prostheses: osseointegration in clinical dentistry*. Chicago: Quintessence, 1985.
 11. Humphris GM, Dyer TA, Robinson PG. The modified dental anxiety scale: UK general public population norms in 2008 with further psychometrics and effects of age. *BMC Oral Health*, 2009;9:20.
 12. Djordjevic F, Stanisic J, Djordjevic A, Vlahovic Z. Pain and justification pain from dental intervention. *Praxis Medica*, 2015;44:27-30.
 13. Bylund CL, Peterson EB, Cameron KA. A practitioner's guide to interpersonal communication theory: an overview and exploration of selected theories *Patient Educ Couns*, 2012;87:261-267.
 14. Ramírez-Carrasco, Butrón-Téllez Girón. Effectiveness of Hypnosis in Combination with Conventional Techniques of Behavior Management in Anxiety/Pain Reduction during Dental Anesthetic Infiltration. *Hindawi Pain Res Manage*, 2017; Article ID 1434015, 5 pages.
 15. Tolstunov L. *Vertical Alveolar Ridge Augmentation in Implant Dentistry: A surgical Manual*. Wiley Blackwell, 2016.
 16. Bazrafshan N, Darby I. Retrospective success and survival rates of dental implants placed with simultaneous bone augmentation in partially edentulous patients. *Clin Oral Implants Res*, 2014;25:768-773.
 17. Becktor JP, Isaksson S, Sennerby L. Survival analysis of endosseous implants in grafted and nongrafted edentulous maxillae. *Int J Oral Maxillofac Implants*, 2004;19:107-115.
 18. Berglundh T, Lindhe J, Ericsson I, Marinello CP, Liljenberg B, Thomsen P. The soft tissue barrier at implants and teeth. *Clin Oral Implants Res*, 1991;2:81-90.
 19. Narayan TV, Narayan S. Longitudinal Evaluation of Implants Placed into Bone Regenerated by the Guided Bone Regeneration (GBR) Technique: A Series of 7 Patients with 13 Implants of at Least Months Follow-up Postloading. *IJOICR*, 2010;1:89-95.
 20. Esposito M, Grusovin MG, Coulthard P, Worthington HV. The efficacy of various bone augmentation procedures for dental implants: a Cochrane systematic review of randomized controlled clinical trials. *Int J Oral Maxillofac Implants*, 2006;21:696-710.
 21. Retzepi M, Donos N. Guided Bone Regeneration: biological principle and therapeutic applications. *Clin Oral Implants Res*, 2010;21:567-576.
 22. Taylor TD, Agar JR. Twenty years of progress in implant prosthodontics. *J Prosthet Dent*, 2002;88:89-98.
 23. Zellin G, Gritli-Linde A, Linde A. Healing of mandibular defects with different biodegradable and non-biodegradable membranes: an experimental study in rats. *Biomater*, 1995;16:601-609.
 24. Misch CE. Influence of biomechanics on implant complications. *Acad Dental Mater Proc*, 2000;14:49-62.
 25. Misch CE. Screw-retained versus cement-retained implant supported prostheses. *Pract Periodontics Aesthet Dent*, 1995;7:15-18.
 26. Serino G, Ström C. Peri-implantitis in partially edentulous patients: association with inadequate plaque control. *Clin Oral Implants Res*, 2009;20:169-174.
 27. Mombelli A, Marxer M, Gaberthuel T, Grunder U, Lang NP. The microbiota of osseointegrated implants in patients with a history of periodontal disease. *J Clin Periodontol*, 1995;22:124-130.
- Conflict of Interests:** Nothing to declare.
Financial Disclosure Statement: Nothing to declare.
Human Rights Statement: All the procedures on humans were conducted in accordance with the Helsinki Declaration of 1975, as revised 2000, and with national ethical committee. Consent was obtained from the patient/s and approved for the current study by national ethical committee.
Animal Rights Statement: None required.
- Received on January 12, 2018.**
Revised on March 2, 2018.
Accepted on October 12, 2018.
-
- Correspondence:
 Aleksandar Đorđević
 Department of Stomatology
 Faculty of Medicine University of Prishtina
 e-mail: sasa-91@live.com