

Intraoral Myeloid Sarcoma with Bilateral Involvement - Case Report

SUMMARY

Background: Myeloid sarcoma (MS) is a solid malignant tumour associated with infiltration of immature myeloid precursor cells in an extramedullary site. The term MS has replaced the term granulocytic sarcoma and chloroma, which were used in the past. MS in the oral cavity is very uncommon, with less of 40 cases reported until recently. **Case Report:** We report the first case, the features, and the diagnostic sequence, of intraoral MS with bilateral palatal involvement, which presented as an initial manifestation, and preceded the appearance of acute myeloid leukaemia (AML). Diagnostic confirmation of such oral mucosal lesions usually requires biopsy, histopathological examination with additional immunohistochemical investigation. MS can occur during the course of acute or chronic myelogenous leukaemia, and myelodysplastic syndromes. In the vast majority of the reported cases, only one site was involved with a single intraoral MS lesion, and the cases predominantly associated with AML. **Conclusion:** The majority of intraoral MS occurs in patients with known AML, but in some of them, presented as an initial manifestation, and preceded the appearance of the disease. Therefore, clinicians should carefully evaluate all unusual oral lesions of unknown origin.

Key words: Myeloid sarcoma, Granulocytic sarcoma, Chloroma, Acute myeloid leukaemia, Oral tumours

Athanasios Pouloupoulos¹, Fotios Iordanidis²,
Dimitrios Andreadis¹,
Konstantinos Antoniadis³

¹ Department of Oral Medicine & Oral Pathology
Dental School, Aristotle University of Thessaloniki
Thessaloniki, Greece

² Gloucestershire Cellular Pathology Laboratory
Cheltenham General Hospital
Cheltenham, United Kingdom

³ Department of Oral & Maxillofacial Surgery
Dental School, Aristotle University of Thessaloniki
Thessaloniki, Greece

CASE REPORT (CR)

Balk J Dent Med, 119-122

Introduction

Myeloid sarcoma (MS) is a solid malignant tumour associated with infiltration of immature myeloid precursor cells in an extramedullary site¹. The term MS has replaced the term granulocytic sarcoma and chloroma, which were used in the past².

MS in the oral cavity is very uncommon with less of 40 cases reported between 1883 and 2014¹. MS can occur during the course of acute or chronic myeloid leukaemia, and myelodysplastic syndromes. In the vast majority of the reported cases, only one site was involved with a single intraoral MS lesion, and the cases predominantly associated with acute myeloid leukaemia (AML)³. Rarely, MS is possible to appear months before the AML manifests, during the course of the illness or represent a leukaemia relapse or remission⁴.

The involvement sites of MS are highly variable and has been reported to affect the skin, bones, upper respiratory tract, and gastrointestinal tract including the oral cavity^{3,5}. Furthermore it has been reported that in 16% of MS cases were diagnosed in the head and neck region, although intraoral MS rarely occurs⁶.

We report the first case, the features, and the diagnostic sequence, of intraoral MS with bilateral palatal involvement, which presented as an initial manifestation, and preceded the appearance of the AML.

Patient Presentation

A 28 year old female was referred by her dentist to our clinic for investigation of a fast growing lesion with bilateral maxillary involvement and protrusion to the

palate for both sides. She had been aware of the lesion for at least five weeks, and was experiencing increasing oral discomfort without pain. The medical history was non-contributory. Before the onset of the oral lesion, the patient did not experience any symptoms suggestive of any systemic abnormalities. There was no history of trauma or dental manipulation related to the site of the lesion.

The intraoral clinical examination revealed two painless sessile, soft in palpation, masses, 2cm in maximum dimension, with identical clinical appearance and location, with no colour changes. Furthermore, there was obvious palatal protrusion of both masses in the first and second molar area (Fig. 1). There were no odontogenic sources or other associated intraoral lesions. Plain radiographs and a computed tomography scan failed to show underlying bone erosion. In addition, the patient performed full blood investigations two months ago, which were ranged within the normal values.

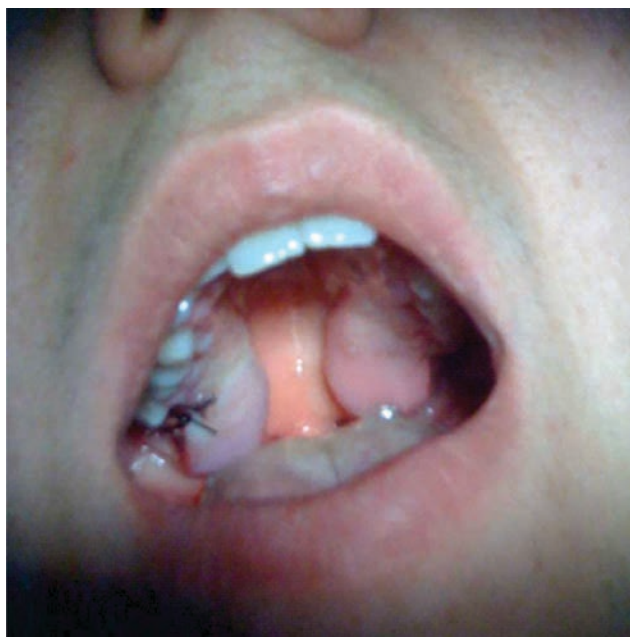

Figure 1. Intraoral myeloid sarcoma with bilateral palatal involvement in the first and second upper molar area

An incisional biopsy was performed, and the microscopic findings of haematoxylin & eosin (H&E) staining demonstrated oral mucosa covered by stratified epithelium; in the underlying corium a cellular proliferation was observed with diffuse and dense infiltration of relatively big and medium size neoplastic blast-like cells, with scant cytoplasm and round-oval nuclei with finely-dispersed chromatin and small distinct nucleoli (Fig. 2 a-c). Furthermore, in the neoplastic cells was observed increased polymorphism, atypia and mitotic

activity. Additional immunohistochemical staining was performed on paraffin sections (Fig. 3) and showed that the cells were positive for MPO (myeloperoxidase), LCA (leukocyte common antigen /CD 45), CD 68, CD 11c, and CD 4 but negative for CD 7, CD 3, CD 20, CD 56, CD 34, CD 117, and Tdt (terminal deoxynucleotidyl transferase).

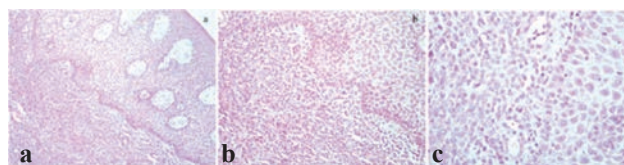


Figure 2. Myeloid sarcoma involving lamina propria of the oral mucosa (a - H&E x 100; b - H&E x 200). The neoplastic cells are medium-sized with scant cytoplasm and round-oval nuclei with finely-dispersed chromatin and small distinct nucleoli (c - H&E x 400)

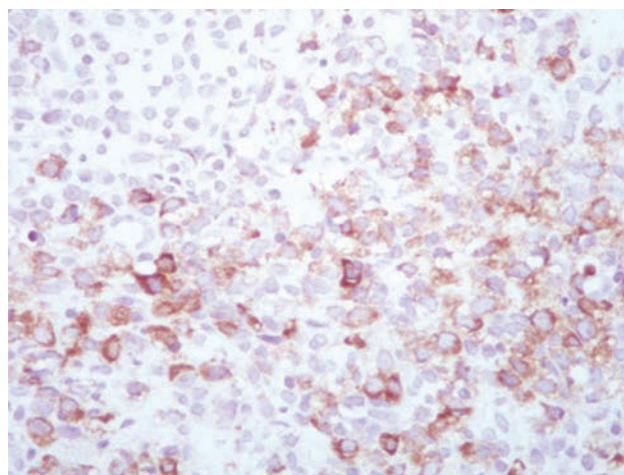


Figure 3. Immunohistochemical stain for myeloperoxidase (MPO) was positive in the MS of the oral mucosa (H & MPO staining x 400)

The patient was immediately referred to haematologists/oncologists for evaluation and further examination. Full blood investigation, myelogram, immunophenotype of monocytes and flow cytometry of peripheral blood, established the diagnosis of AML (M5b) and the bilateral intraoral lesions were confirmed as MS. A computed tomography (CT) scan detected no other areas affected by the disease. Further investigations for molecular markers FMS-like tyrosine kinase 3 gene (FLT3) and nucleophosmin 1 gene (NPM1) were negative. The induction therapy consisted of cytarabine (Ara-C 175mg/m² every 12 hours for 7 days) plus idarubicin (17,5 mg/m² days 1, 3, 5), followed by high dose cytarabine (Ara-C 3 g/m² every 12 hours for 3 days) and idarubicin (17,5 mg/m² for 3days).

The patient after 1 year is currently in good condition with remission of the oral MS. An informed consent was obtained from the patient for the case presentation.

Discussion

The majority of MS cases occur in association with AML or myelodysplastic/myeloproliferative diseases⁷. The occurrence of intraoral MS as multiple masses involving multiple sites is extremely rare, with only 2 reported cases in the literature^{3,8}. Intraoral MS usually occurs concomitantly with or subsequent to the development of AML; it is most seen in patients with the subtype AML-M1 (myeloblastic leukaemia without maturation) or AML-M2 (myeloblastic leukaemia with maturation)⁵, whereas rarely, it precedes the appearance of AML as in our case. To our knowledge this is the first case of intraoral MS with bilateral maxillary involvement, which presented as an initial manifestation, and preceded the appearance of the AML.

Most articles reported MS presenting as symptomatic or asymptomatic mass and mucosa ulceration with colour varying among brown, red, black and pale grey⁹. The differential diagnosis would include benign tumours such as pyogenic granuloma, granulomatous epulis and peripheral giant granuloma, as well as malignant neoplasms such as sarcomas, lymphomas, epidermoid carcinomas and metastasis of other neoplasms¹⁰. Diagnosis of intraoral MS may be difficult, especially when it presents as an isolated finding and with no history of haematological disorders or peripheral blood or bone marrow involvement of myeloproliferative disorders. Consequently the diagnosis has clinical relevance because it can be the first sign of an AML. The lesion occurs more often in women; the age of affected patients ranges widely (3 to 89 years)¹¹. The maxillary and mandibular gingivae were the most common sites involved, followed by the palate and very rarely the cheek³.

Histologically, MS usually is characterized by sheets of relatively monomorphic intermediate to large size polyhedral cells with irregular nuclear contours, vesicular chromatin, variably prominent nucleoli, and frequent mitotic figures¹². The diagnosis of MS may be complicated by the diversity and inconsistency of its morphologic features and may be misdiagnosed as malignant lymphoma, Ewing's sarcoma, acute lymphoblastic leukaemia, or other small blue cell tumors¹⁰. Therefore additional immunohistochemical studies may help in reaching to a definitive diagnosis because myeloid cells are reactive to antibodies against lysozyme, myeloperoxidase and chloroacetate esterase. Also MS myeloblasts usually express myeloid-associated antigens such as CD43, but are not reactive with lymphoid antigens³. In addition, immunophenotyping with flow cytometry and cytogenetics may contribute to a definitive diagnosis. Furthermore imaging studies with Magnetic Resonance Imaging (MRI) scans of MS exhibit low signal intensity on T2-weighted images, which helps to rule out inflammatory lesions¹³.

The prognosis of patients with MS is poor and strictly related to the clinical course of AML¹⁴. In patients with known AML at an older age, the appearance of MS is a significant adverse prognostic factor, moreover it has been reported that patients with multiple MS lesions have a shorter survival than those with only one tumor⁶. The treatment of MS depends on the patient's medical history and clinical presentation, applying chemotherapy protocols similar to that used for AML¹⁰. Systemic chemotherapy and local radiotherapy remain the main treatment modalities, although a uniform treatment protocol for the intraoral MS doesn't exist². The use of imatinib mesylate has been proposed as the therapeutic agent of choice for MS in patients with a history of chronic myeloid leukaemia (CML), even if they are free of CML³.

Conclusion

Although the incidence of intraoral MS is rare, its occurrence should not be disregarded. The majority of intraoral MS occurs in patients with known AML, but in some of them, MS may be presented as an initial manifestation, and it may precede the appearance of the disease.

Furthermore, as the survival rates of patients with leukaemias increase, the incidence of rare intraoral tumours, such as MS, may become more common. Therefore, clinicians should carefully evaluate all unusual oral lesions of unknown origin. Diagnostic confirmation of such mucosal lesions usually requires biopsy, histopathological examination with additional immunohistochemical investigations.

References

1. Yap M, Hewson I, McLean C. Oral myeloid sarcoma: two case reports. *Aust Dent J*, 2014;59:511-515.
2. Papamanthos KM, Kolokotronis EA, Skulakis EH, Fericean AAM, Zorba TM, Matiakis TA. Acute Myeloid Leukaemia Diagnosed by Intra-Oral Myeloid Sarcoma. A Case Report. *Head and Neck Pathol*, 2010;4:132-135.
3. Xie Z, Zhang F, Song E, Ge W, Zhu F, Hu J. Intraoral granulocytic sarcoma presenting as multiple maxillary and mandibular masses: a case report and literature review. *Oral Surg Oral Med Oral Pathol Oral Radiol Endod*, 2007;103:e44-48.
4. Tong AC, Lam KY. Granulocytic sarcoma presenting as an ulcerative mucogingival lesion: Report of a case and review of the literature. *J Oral Maxillofac Surg*, 2000;58:1055-1058.
5. Carmona IT, Teijeiro JC, Dios PD, Feijoo JF, Posse JL. Intra-alveolar granulocytic sarcoma developing after tooth extraction. *Oral Oncol*, 2000;36:491-494.

6. Colella G, Tirelli A, Capone R, Rubini C, Guastafierro S. Myeloid sarcoma occurring in the maxillary gingiva: a case without leukemic manifestations. *Int J Hematol*, 2005;81:138-141.
7. Breccia M, Mandelli F, Petti MC, D'Andrea M, Pescarmona E, Pileri SA, Carmosino I, Russo E, De Fabritiis P, Alimena G. Clinico-pathological characteristics of myeloid sarcoma at diagnosis and during follow-up: report of 12 cases from a single institution. *Leuk Res*, 2004;28:1165-1169.
8. Eisenberg E, Peters ES, Krutchkoff DJ. Granulocytic sarcoma (chloroma) of the gingiva: report of a case. *J Oral Maxillofac Surg*, 1991;49:1346-1350.
9. Koudstaal MJ, van der Wal KGH, Lam KH, Meeuwis CA, Speleman L, Levin MD. Granulocytic sarcoma (chloroma) of the oral cavity: report of a case and literature review. *Oral Oncol EXTRA*, 2006;42:70-77.
10. Jordan RC, Glenn L, Treseler PA, Regezi JA. Granulocytic sarcoma: case report with an unusual presentation and review of the literature. *J Oral Maxillofac Surg*, 2002;60:1206-1211.
11. Osterne RLV, Matos-Brito RG, Alves APNN, Nogueira TNAG, Rocha-Filho FD, Meneses FA, Sousa FB. Oral granulocytic sarcoma: a case report. *Med Oral Patol Oral Cir Bucal*, 2009;14:e232-235.
12. Brunning RD, Matutes E, Head D, Flandrin G, Harris NL, Vardiman J. Acute myeloid leukemia not otherwise categorised. In: Tumors of hematopoietic and lymphoid tissues edited by Jaffe ES, Stein H, Vardiman JW. Lyon: IARC Press, 2001; pp. 104-105.
13. Lee SS, Kim HK, Choi SC, Lee JI. Granulocytic sarcoma occurring in the maxillary gingiva demonstrated by magnetic resonance imaging. *Oral Surg Oral Med Oral Pathol Oral Radiol Endod*, 2001;92:689-693.
14. Srinivasan B, Ethunandan M, Anand R, Hussein K, Ilankovan V. Granulocytic sarcoma of the lips: report of an unusual case. *Oral Surg Oral Med Oral Pathol Oral Radiol Endod*, 2008;105:e34-36.

Received on May 31, 2016.

Revised on August 1, 2016.

Accepted on October 2, 2016.

Correspondence:

Athanasios Pouloupoulos
Dental School, Aristotle University of Thessaloniki
Thessaloniki, 54124 Greece
E-mail: akpoul@yahoo.gr