

# Preprosthetic Laser Assisted Mandibular Vestibuloplasty

## SUMMARY

*A prosthetic treatment of the edentulous mandible can be very challenging. In cases with inadequate buccal depth, a necessary deepening of the oral vestibule can be achieved by surgically detaching the soft tissue attachments. A preprosthetic vestibuloplasty is usually done surgically by scalpel. With the permanent advancement of laser technology, a laser vestibuloplasty has become a preferred surgical procedure. The aim of this report was to present individuality of a mandible vestibuloplasty performed with Er:YAG laser.*

*A 69-year-old patient was referred to the University Department of oral surgery after several previous unsuccessful attempts to stabilize his lower denture. The intraoral assessment revealed complete mandibular edentulism and a shallow vestibule with sufficient bone height in the anterior region. Since the patient's financial resources precluded dental implants, mandible anterior vestibuloplasty was planned to deepen the vestibule thus increasing the anatomic basis for prosthetic rehabilitation. The vestibuloplasty was performed with Er-Yag Laser (Fotona Fidelis III). The laser ablation started at the mucogingival junction. The soft tissue bands were ablated layer by layer till the desired vestibular depth was achieved. There was no need for suturing. No protective barrier was placed. The postoperative recovery was symptomless, without pain, oedema, or signs of infection. Four weeks after surgery, the healing process was completed and sufficient anterior vestibular depth was gained and maintained. Er:YAG laser assisted vestibuloplasty was a minimally invasive surgical procedure. The fast healing with minimal scarring resulted and a sufficient vestibular depth was gained.*

**Keywords:** Mandibular Vestibuloplasty, Er:Yag Laser, Preprosthetic Surgery

**M. Kacarska<sup>1</sup>, O. Dimitrovski<sup>1</sup>,  
D. Popovic Monevska<sup>2</sup>**

<sup>1</sup>Faculty of Dentistry  
Department of Oral Surgery, Skopje, FYROM  
<sup>2</sup>Faculty of Dentistry  
Department of Maxillofacial Surgery  
Skopje, FYROM

## CASE REPORT (CR)

**Balk J Dent Med, 2016; 20:182-185**

## Introduction

A prosthetic treatment of edentulous mandible can be very challenging. Inadequate buccal or lingual depth in the mandible is one of the main circumstances that preclude optimal prosthetic rehabilitation. In edentulous mandibles with high mucosa insertion preprosthetic surgery is indicated. Vestibuloplasty is a surgical procedure wherein the oral vestibule is deepened by changing the soft tissue attachments on the buccal and/or lingual aspects of the jaw<sup>1-3</sup>.

A variety of conventional vestibuloplasty techniques have been advocated in the literature. The most

common was Kazanjian's technique by supra-periosteal dissection and its modifications. Other techniques include submucosal vestibuloplasty and soft tissue grafting procedures<sup>4</sup>. There are several shortcomings of the conventional techniques, such as the exposed large wound surface, pain and discomfort, followed by prolonged postoperative healing. Sometimes, the exposed surface heals by granulation and contracture of the wound margins takes place<sup>5</sup>. Consequently, the prosthetic rehabilitation is postponed till completion of the healing process, which can be unpredictable.

The advent of new technologies with introduction of lasers in dentistry have enabled practitioners to use

various types of lasers (diode laser, Er:YAG, Nd:YAG) for vestibuloplasty procedures<sup>6</sup>. Laser vestibuloplasty with the Er:YAG laser represents a contemporary non-invasive alternative to conventional soft tissue surgery. Tissue ablation with erbium laser was first described by Venugopalan<sup>7</sup>. At a wavelength of 2.94  $\mu\text{m}$  the Er:YAG laser has the highest specificity for water absorption of all the mid-infrared lasers. The high water content in oral soft tissues makes this laser a useful tool in oral soft surgery, while the finest low pulse energy and high repetition rates makes erbium an extremely precise tool suitable for delicate procedures<sup>8</sup>.

The aim of this report was to present individuality of a mandible vestibuloplasty performed with Er:YAG laser.

## Patient's Presentation

A 69-year-old patient was referred to the University Department of oral surgery after several previous unsuccessful attempts to stabilize his lower denture. The intraoral assessment revealed complete mandibular edentulism and a shallow vestibule with sufficient bone height in the anterior region (Fig. 1). Since the patient's financial resources precluded dental implants, mandible anterior vestibuloplasty was planned to deepen the vestibule thus increasing the anatomic basis for prosthetic rehabilitation.

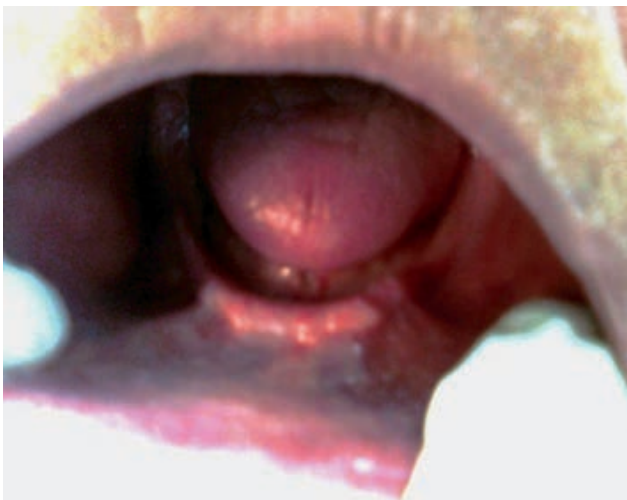

Figure 1. Preoperative view of the shallow mandibular anterior vestibule

The patient was a diabetic, with a glucose level of 6.5 mmol/l, measured on the day of surgery.

## Surgical Procedure

Local anaesthesia of the surgical field was achieved with bilateral mental blocks with 3% scandonest. Necessary laser protective equipment was ensured, comprising that

laser safety glasses were worn by the clinician and the patient, and proper precautions were taken.

Mandibular anterior vestibuloplasty was performed with Er:YAG Fotona Fidelis III (Fig. 2), a non-contact hand piece R02, short pulse mode (SP), pulse energy of 200 mj, and frequency of 2 Hz, without water and air spray (Tab. 1).

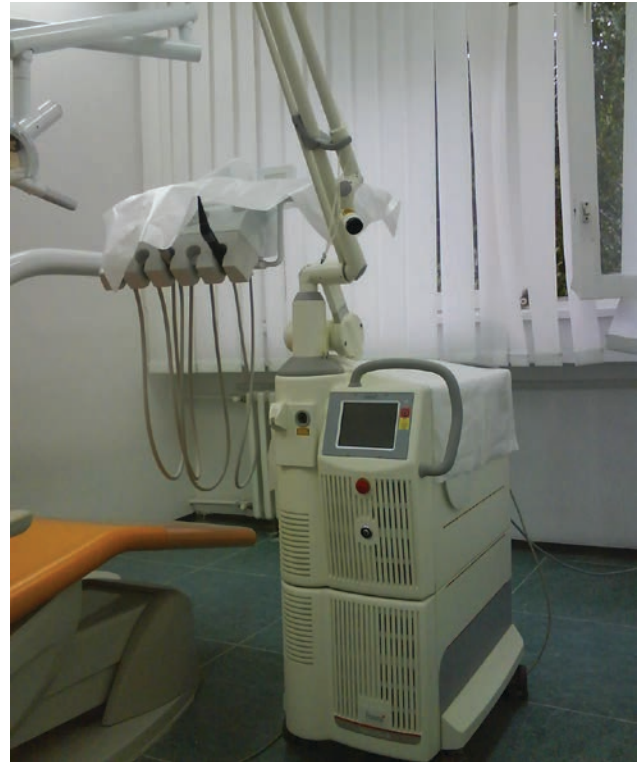

Figure 2. Fotona Fidelis III laser

Table 1. Laser parameters

Laser source	Er:YAG (2940 nm)
VSP mode	SP, LP
Pulse energy	200 mJ
Frequency	2 Hz
Hand piece	R02
Water/air spray setting	None

The laser ablation started at the mucogingival junction (Fig. 3). The soft tissue bands were ablated layer by layer by moving the laser tip across the tissue surface till the desired depth was gained, simultaneously pulling the lower lip outwards (Fig. 4). After lasing, the area was coagulated, with defocused VLP mode (Fig. 5). The patient was advised to avoid sour beverages, and to take pain medications if necessary. Postoperative follow ups were made on a weekly basis, until the healing was completed (Fig. 6).

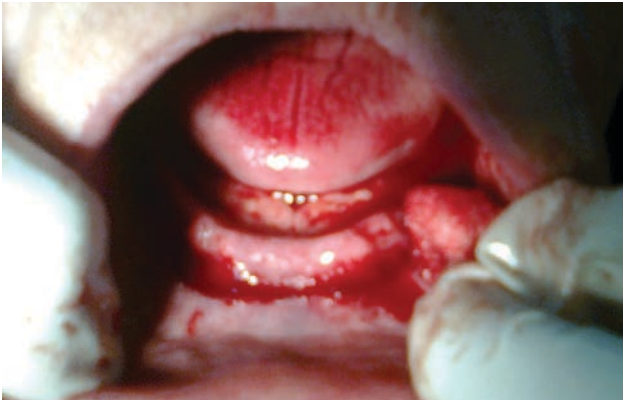


Figure 3. Intraoperative view - ablation at the mucogingival junction

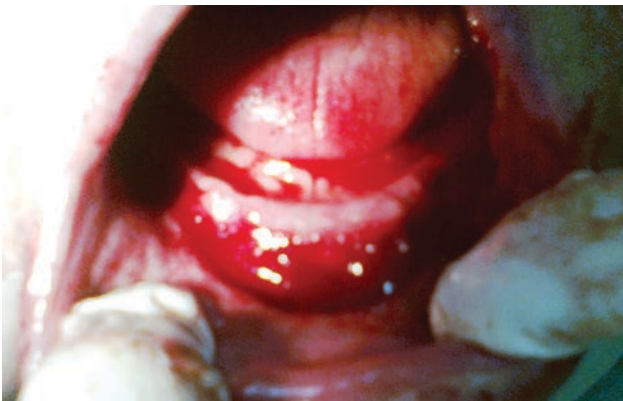

Figure 4. Surgery in progress. Deeper tissue layers exposed

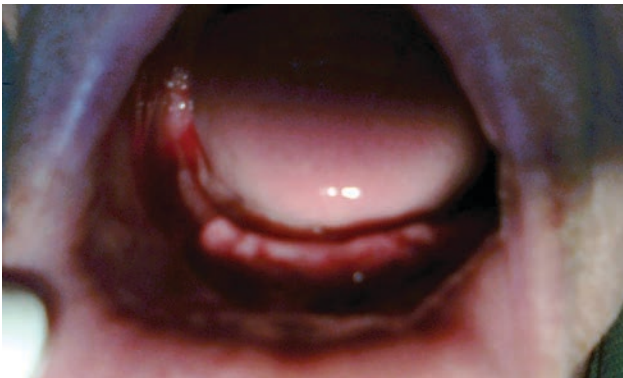


Figure 5. Completed vestibuloplasty with evident subsided bleeding

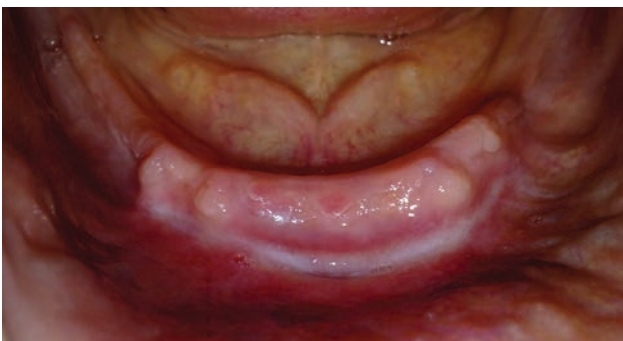

Figure 6. 4 weeks after surgery the healing was completed. Sufficient vestibular depth with a noticeably delicate scar

## Discussion

Prosthetic rehabilitation of an edentulous mandible can be a delicate procedure when proper vestibule depth is absent. Because of the painful and prolonged healing following conventional vestibuloplasty, a laser vestibuloplasty with Erbium:YAG is recommended<sup>6</sup>. When used in oral soft tissue surgery, the Er:YAG laser targets the chromophore of water selectively instead of the extracellular matrix of collagen. This produces an instantaneous vaporization of the water to a depth of about 4  $\mu\text{m}$  per pulse<sup>7</sup>. The laser optical energy is converted to local thermal energy in a confined tissue volume, which results in instantaneous tissue degradation or ablation, accompanied with explosive ejection of the degraded cellular components and heated vaporous material. A high absorption peak in the water, minimizes the thermal damage to the tissue, which results in improved healing<sup>9</sup>.

Er:Yag has a high absorption peak in the water, and in bacteria cells as well. During the Er:YAG tissue interaction, the bacteria in the path of the beam are destroyed as the water within the bacterial cells undergoes the same instantaneous phase change; accordingly, the surgical field is sterilized<sup>10,11</sup>. The bactericidal properties of erbium enable healing without infection. The haemostatic properties of erbium are considered marginal<sup>9,12</sup>, but the significance of bleeding for regeneration can't be neglected.

Even though the laser vestibuloplasty we performed was time consuming in comparison to conventional techniques, it validated the numerous and irreplaceable advantages of Er: YAG laser surgery. The treatment was painless and quite comfortable, with minimum amounts of anaesthetic used. As the patient was diabetic, it was reasonable to expect intraoperative bleeding. The bleeding somewhat compromised the visibility during surgery. At the completion of the procedure, coagulation of the surgical surface was achieved with a very long pulse (VLP) used in defocused mode. No sutures were needed, and no protective barrier was placed.

The postoperative period was uneventful, without pain or signs of infection. Sealing of the blood and lymph vessels minimized the postoperative swelling, while sealing of the nerve endings reduced pain and discomfort<sup>13</sup>. The healing was accelerated. Laser wound healing is similar to conventional (scalpel) wound healing, but with less inflammation and reduced scar formation<sup>13</sup>. The fibrin layer was noticeable on the following day, and partial epithelization was evident after 2 weeks. The healing process with delicate scar formation was completed 4 weeks after surgery. The vestibular depth was gained and maintained without contraction (Fig. 6). A new stable prosthesis was made as a final step of prosthetic rehabilitation.

## Conclusion

Er:YAG laser assisted vestibuloplasty was a minimally invasive surgical procedure with our patient. The fast healing with minimal scarring resulted in a sufficient vestibular depth, fulfilling patient's aesthetic and functional needs.

## References

1. Yilmaz E, Ozelik O, Comert M, Ozturan S, Seydaoglu G, Teughels W, et al. Laser-assisted laterally positioned flap operation: a randomized controlled clinical trial. *Photomed Laser Surg*, 2014; 32:67-74.
2. Hillerup S. Preprosthetic mandibular vestibuloplasty with split-skin graft: A two-year follow-up study. *Int J Oral Maxillofacial Surg*, 1987; 16:270-278.
3. Hillerup S, Hjørtning-Hansen E, Solow B. Influence mandibular vestibuloplasty. A 5-year clinical and radiological follow up study. *Int J Oral Maxillofac Surg*, 1990; 19:212-215.
4. Hjørtning-Hansen E, Adawy AM, Hillerup S. Mandibular vestibule-lingual sulcoplasty with free skin graft: A five-year clinical follow-up study. *J Oral Maxillofac Surg*, 1983; 41:173-176.
5. Froshi T, Kercher A. The optimal vestibuloplasty in preprosthetic surgery of the mandible. *J Craniomaxillofacial Surgery*, 1997; 25:85-90.
6. Devaki VN, Balu K, Ramesh SB, Arvind RJ, Venkatesan. Pre-prosthetic surgery: Mandible. *Journal of Pharmacy & Bioallied Sciences*, 2012; 4(Suppl 2):S414-S416.
7. Venugopalan V. Pulsed laser ablation of tissue: surface vaporization or thermal explosion? *SPIE Proc*, 1995; 2391:184-189.
8. Aoki A, Watanabe H, Ishikawa I. Er:YAG clinical experience in Japan: a review of scientific investigations. *SPIE Proc*, 1998; 3248:40-45.
9. Niemz MH. *Laser-Tissue Interactions: Fundamentals and Applications (Biological and Medical Physics)*. 2<sup>nd</sup> ed. Berlin, Germany: Springer-Verlag, 2002; pp 45-80.
10. Walkinski C. Dental lasers: Possibilities and benefits. *Journal of Massachusetts Dental Society*, 2004; 53(3):7-9.
11. Ando Y, Aoki A, Watanabe H, et al. Bactericidal effect of Er:YAG laser on periodontopathic bacteria. *Lasers Surg Med*, 1996; 19:190-200.
12. Clayman L, Kuo P, eds. *Lasers in Maxillofacial Surgery and Dentistry*. New York, NY: Thieme Medical Pub, 1997; pp 19-28.
13. Kesler G, Koren R, Kesler A, et al. Periodontal plastic surgery: thermal effect analysis using Erbium:YAG Kesler's handpiece. Histochemical evaluation by Picrosirius red stain and polarization microscopy for collagen determination. *SPIE Proc*, 2000; 3910:2

Received on August 9, 2016.

Revised on October 1, 2016.

Accepted on October 12, 2016.

Correspondence Author:

Marina Kacarska  
Slavejko Arsov 30½  
1000 Skopje,  
FYR Macedonia  
E-mail: marina\_kacarska@yahoo.com