

The Use of Cone-Beam Computed Tomography in Furcation Defects Diagnosis

SUMMARY

Background: The use of cone-beam computed tomography (CBCT), as an additional diagnostic tool in daily dental practice, has expanded rapidly in recent years. Since CBCT allows assessment of dento-maxillofacial structures in three-dimensional manner, its use may be very tempting in alveolar bone furcation defects (FDs) diagnosis.

Aim: The aim of this study was to determine the impact of clinical experience and experience with CBCT on FD detection in patients with periodontitis.

Material and Methods: Fifteen patients with chronic generalized severe periodontitis were included in the study. In total, 168 furcation sites were analyzed on CBCT images by a previously trained senior year undergraduate student (O1) and a PhD student with three years of CBCT experience (O2), and compared to clinical findings (probing). CBCT images were analyzed on two separate occasions, within a 7-day interval. FDs were assessed both clinically and on CBCT images, using a dichotomous scale (present/absent). Intraobserver agreement for each observer was calculated by using Kappa coefficient (k). Interobserver agreement and agreement between CBCT and clinical findings for both observers were calculated.

Results: Kappa coefficient value for both observers indicated a high intraobserver agreement ($k_1=0.75$; $k_2=0.94$). Interobserver agreement of CBCT image analyses was present in 72.6% (73.0% in maxilla, 71.7% in mandible). Agreement between CBCT image analyses and clinical findings for O1 was 48.8% and 51.2% for O2.

Conclusion: It can be assumed that clinical experience and CBCT proficiency do not have an impact on FD detection on CBCT images, if an appropriate training was previously performed.

Keywords: CBCT, Furcation defect, Furcation involvement, Periodontitis

M. Cimbaljevic, J. Mistic, S. Jankovic,
N. Nikolic-Jakoba

School of Dental Medicine
Department of Periodontology
University of Belgrade
Belgrade, Serbia

ORIGINAL PAPER (OP)

Balk J Dent Med, 2016; 20:143-148

Introduction

Periodontitis is a chronic inflammatory disease of the tooth's supporting tissues. The continuous process of alveolar bone loss leads to the formation of bone defects around the teeth and in the interradicular region¹. The progression and expansion of periodontal disease into the bi- or trifurcation region of multirooted teeth is called furcation involvement (FI).

FI may be detected during the clinical assessment, while the destruction of periodontal tissue in the region

between the roots can be detected as a furcation defect (FD) on radiographs². Clinical assessment is performed by probing using a Nabers probe, which isn't always easy and accurate due to limited physical access to furcation region, morphological variations and errors in measurement³. Radiographic diagnosis relies on two-dimensional (2D) and three-dimensional (3D) imaging modalities. The main limitation and major drawback of currently used conventional intraoral imaging methods for FD is the representation of a 3D structure in a 2D image, which leads to anatomical structures overlap⁴. Precise

assessment of FI is of great importance due to its impact on prognosis, treatment plan and outcome.⁴ With this in mind, the emphasis should be on exploring additional diagnostic methods and modalities for FD assessment.

3D diagnostic methods, such as cone-beam computed tomography (CBCT), have been introduced recently in periodontology^{5, 6}. CBCT is a radiographic tool that ensures satisfying imaging quality while exposing patients to reduced radiation doses, when compared to conventional CT machines⁷. Several *in vitro* studies have confirmed the diagnostic accuracy of CBCT in the detection and the quantification of periodontal defects^{5, 6, 8, 9}. Likewise, CBCT seems to be a promising diagnostic method in FD assessment, especially in maxillary molars¹⁰.

Previous *in vitro* and *in vivo* studies showed that CBCT method may provide additional information about the shape and extent of the furcation lesion, and that it also made a better basis for choosing an adequate treatment plan, when compared to traditional assessment of FI (clinical assessment and periapical radiographs (PA))^{3, 11, 12}. In the previously mentioned studies a multiobserver approach was chosen to explore the possibilities and accuracy of the CBCT method in periodontology by engaging researchers with different levels of clinical experience and experience with CBCT^{3, 11, 12}. However, these studies provide scarce evidence concerning the effect of observers' experience on FD detection.

Therefore, the aim of this study was to determine the impact of clinical experience and experience with CBCT on FD detection in patients with periodontitis.

Material and methods

The study group was comprised of fifteen patients (11 women, 4 men, average age 44.5 years) with chronic generalized severe periodontitis¹³. Selection was based on the following criteria: at least two intrabony defects with probing depth ≥ 6 mm in both jaws indicated for surgery, no systemic disease, no pregnancy and lactation. Included patients were selected from the pool of patients at the Department of Periodontology, School of Dental Medicine, University of Belgrade. The study was approved by the Ethics Research Committee of the School of Dental Medicine, University of Belgrade, Serbia (ethics approval № 36/2). All study participants were informed of the examination purpose and signed an informed consent.

Clinical assessment of FI

Patients received hygiene instruction, scaling and root planning with ultrasonic device and hand instruments. Six weeks after initial periodontal therapy, when decision making related to the need for periodontal surgery was

made, 30 upper molars at three furcation sites (buccal, mesiopalatal and distopalatal) and 36 lower molars at two furcation sites (buccal and oral) were analyzed using curved Nabers probe (PQ2N; PH-Friedy Europe, Rotterdam, Netherlands)¹³⁻¹⁵. A total of 168 furcation sites were analyzed by two independent, previously calibrated, experienced periodontists ($k=0.697$). The existence of FI was established when periodontal pocket detected by inserting the probe horizontally into the furcation. The clinical findings were recorded by using dichotomous scale: present/absent.

CBCT assessment of FD

CBCT scanning was performed using imaging system SCANORA 3Dx (Soredex, Tussula, Finland) and scanning parameters from the Table 1. CBCT image analysis was performed using recommended software (OnDemand3D, Cybermed, Korea) and 17" monitor (VA2232WA-LED, ViewSonic) with 1.280x1.024 resolution in a darkened room. Two observers with different working experience in the clinical and CBCT assessment were analyzed furcation regions of the upper and lower molars on CBCT images. The first observer was senior year undergraduate student (O1), whilst the second was a PhD student with a three-year experience in working with CBCT (O2). Both observers were briefly trained, and the protocol for the analysis of CBCT images was presented in detail to each of them before the radiographic evaluation. The existence of FD was recorded when the radiolucency observed between the roots of teeth. Each of the observers analyzed the CBCT images on two occasions, separately, with an interval of seven days, and was blinded for the clinical evaluation. FDs were assessed on CBCT images in all three planes (axial, sagittal, coronal) using a dichotomous scale: present/absent.

Table 1. Scanning parameters

| | |
|-------------------|--------|
| FOV (mm) | 80x100 |
| Voxel size (mm) | 0,25 |
| Tube voltage (kV) | 90 |
| Tube current (mA) | 10 |
| Scanning time (s) | 2,4 |

Statistical analysis

Statistical calculations were carried out using IBM SPSS, version 20. Intraobserver agreement for each observer was calculated by using Kappa coefficient (k) according to the following criteria: <0.10 = no agreement; 0.10 to 0.40 = poor agreement; 0.41 to 0.60 = moderate agreement; 0.61 to 0.80 = strong agreement; and 0.81 to

1.00 = excellent agreement¹⁶. Interobserver agreement and agreement between CBCT data and clinical findings for both observers were calculated (ANOVA test, percentage).

Results

High intraobserver agreement for both observers was calculated using Kappa coefficient (strong agreement

for the O1 k1 = 0.75, excellent agreement for the O2 k2 = 0.94). The number and percentage of FDs detected on CBCT images by both observers are presented in the Table 2. Agreement between the observers in detection of FDs on CBCT images was 72.6 % for both jaw (Table 2). Interobserver agreement was slightly higher in the maxilla (73.0%) compared to mandible (71.7%) (Table 2). There was no statistically significant difference between observers in detection of FDs on CBCT images.

Table 2. Number (and percentage) of FD detected on CBCT images by both observers and their agreement, according to the jaw (maxilla / mandible)

| CBCT O ₁ ASSESSMENT | CBCT O ₂ ASSESSMENT | | | | | |
|-----------------------------------|--------------------------------|------------|-------------|------------|--------------|-------------|
| | MAXILLA | | MANDIBLE | | TOTAL | |
| | ABSENT | PRESENT | ABSENT | PRESENT | ABSENT | PRESENT |
| ABSENT | 8 (7.3%) | 14 (13.0%) | 4 (6.7%) | 9 (15.0%) | 12 (7.1%) | 23 (13.7%) |
| PRESENT | 15 (13.0%) | 71 (65.7%) | 8 (13.3%) | 39 (65.0%) | 23 (13.7%) | 110 (65.5%) |
| TOTAL | 108 (100.0%) | | 60 (100.0%) | | 168 (100.0%) | |
| AGREEMENT | 73.0% | | 71.7% | | 72.6% | |

Table 3. Number (and percentage) of FI detected clinically and FD detected on CBCT images by the first observer (O1) and agreement between the methods, according to the jaw (maxilla / mandible).

| CBCT O ₁ ASSESSMENT | CLINICAL ASSESSMENT | | | | | |
|-----------------------------------|---------------------|------------|-------------|------------|--------------|------------|
| | MAXILLA | | MANDIBLE | | TOTAL | |
| | ABSENT | PRESENT | ABSENT | PRESENT | ABSENT | PRESENT |
| ABSENT | 20 (18.5%) | 2 (1.9%) | 13 (21.7%) | 0 (0.0%) | 33 (19.6%) | 2 (1.2%) |
| PRESENT | 50 (46.3%) | 36 (33.3%) | 34 (56.7%) | 13 (21.6%) | 84 (50%) | 49 (29.2%) |
| TOTAL | 108 (100.0%) | | 60 (100.0%) | | 168 (100.0%) | |
| AGREEMENT | 51.8% | | 43.3% | | 48.8% | |

Table 4. Number (and percentage) of FI detected clinically and FD detected on CBCT images by the second observer (O2) and agreement between the methods, according to the jaw (maxilla / mandible)

| CBCT O ₂ ASSESSMENT | CLINICAL ASSESSMENT | | | | | |
|-----------------------------------|---------------------|------------|-------------|------------|--------------|------------|
| | MAXILLA | | MANDIBLE | | TOTAL | |
| | ABSENT | PRESENT | ABSENT | PRESENT | ABSENT | PRESENT |
| ABSENT | 23 (21.3%) | 0 (0.0%) | 12 (20.0%) | 0 (0.0%) | 35 (20.8%) | 0 (0.0%) |
| PRESENT | 47 (43.5%) | 38 (35.2%) | 35 (58.3%) | 13 (21.7%) | 82 (48.8%) | 51 (30.4%) |
| TOTAL | 108 (100.0%) | | 60 (100.0%) | | 168 (100.0%) | |
| AGREEMENT | 56.5% | | 41.7% | | 51.2% | |

Agreement between clinical findings and CBCT data for the first observer

Agreement between the clinical and CBCT evaluation of furcation regions for the O1 was 48.8%, where 50% of FDs were detected on CBCT images, but not during the clinical examination (Table 3). Higher agreement between diagnostic methods was detected in maxilla (51.8%) than in the mandible (43.3%) (Table 3).

The differences between tested methods was higher in the mesiopalatal sites of maxillary molars (agreement 44%), than in the in the buccal and distopalatal sites (agreement 55%) (Figure 1). The highest disagreement was presented in the examined furcation sites of mandibular molars, where the agreement between testing methods was the same in buccal and oral sites (43%) (Figure 1).

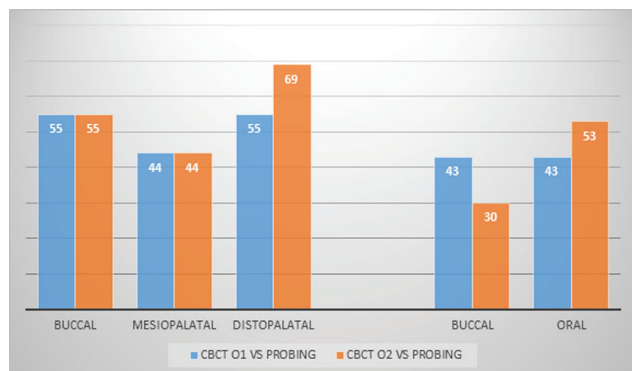


Figure 1. Agreement in percentage between clinical (probing) and CBCT assessment for both observers, according to the site in maxillary molars (buccal, mesiopalatal, distopalatal) and the site in mandibular molars (buccal, oral)

Agreement between clinical findings and CBCT data for the second observer

Agreement between clinical and CBCT data obtained by the O2 was 51.2% (56.5% for maxillary molars, 41.7% for mandibular molars) (Table 4). The highest difference between diagnostic methods was found in the buccal sites of the mandibular molars (30%), while the distopalatal sites showed the strongest agreement between the CBCT findings and clinical evaluation (69%) (Figure 1).

Discussion

For the past two decades, the use of CBCT method in the periodontal region was mainly related to the assessment of intrabony and FDs caused by periodontitis^{3, 5, 6, 11, 17-19}. CBCT images are supposed to provide the 3D presentation of periodontal defects, which may help in creating an appropriate treatment plan²⁰. However, CBCT image analysis requires the knowledge of the software recommended by the manufacturer. The fact that clinical detection of FI is challenging even for the experienced dentists, raises the question whether the clinical experience and experience in working with CBCT method have an impact on the accurate detection of FDs on CBCT images.

In the present study, two observers, with different level of clinical and CBCT experience, analyzed the furcation regions of upper and lower molars on CBCT images. The study results showed that there was no statistically significant difference between the observers in detection of FDs when CBCT was used. High intraobserver agreement for each observer ($k_1=0.75$ and $k_2=0.94$) and high interobserver agreement (72.6%) in detection of FD on the CBCT images were also found. These results may be explained with the fact that both

observers received detailed instructions regarding the CBCT image analysis during the training session.

Furthermore, the results in the present study showed that there were no statistically significant differences between the observers when compared to clinical findings. These results are in accordance with the results of study Cimbaljevic et al.¹⁴, where FDs were more frequently detected on CBCT images than during the clinical examination. Almost half of the FDs were detected on CBCT images by both observers (50% by the O1, 48.8% by the O2), but not during the clinical examination by means of probing. Namely, only 2.1% of FI was detected clinically, but were not seen as FD on CBCT images during the radiographic evaluation by the O1. All the differences between the diagnostic methods was related to detection of FD on CBCT images, but not clinically by the O2. Likewise, stronger agreement between the diagnostic methods was observed in maxilla than in the mandible by both observers (Tables 3 and 4).

Regarding the all examined furcation sites, results showed that the highest differences between the observers was in the distopalatal region of maxillary molars (55% of FDs were detected by the O1, and 69% were detected by the O2). Also, the differences between the observers were detected in the buccal and oral region of the mandibular molars. Although these differences were not statistically significant, detection of FDs requires caution because of the possibility of "over-diagnosis", while the underestimation may lead to inadequate treatment plan¹⁴.

The accuracy of the CBCT method in the analysis of FDs was assessed in several *in vivo* studies, and showed that surgical findings were in accordance with CBCT data in more than 80% of cases, which indicated that this method could have the potential in treatment decision making^{3, 10, 11}. In the studies of Walter et al.^{10, 11}, CBCT image analysis were conducted by two periodontist, whilst two trained radiologists, analyzed the furcation regions in the study of Qiao et al.³. Although CBCT image analysis were carried out by several researchers in the mentioned studies, the influence of clinical experience and experience in working with CBCT in analyzing FDs was not investigated.

Results of the present study are in accordance with the existing results in the literature^{17, 20, 21}. In the study of Guo et al.¹⁷ four postgraduate students with different CBCT experience (three majoring in dental and maxillofacial radiology and one in periodontology) analyzed the level of alveolar bone on CBCT images¹⁷. Although all the researchers were post-graduates at different grades, intraobserver and interobserver variability was not found¹⁷. In another study, the dimensions of combined alveolar bone defects were measured on CBCT images and PA radiographs by three trained observers (the radiologist with two years of professional experience, and two master students in oral radiology)²⁰. Agreement between the observers regarding

the identification of the pattern of alveolar bone loss and combined defect detection was about 100%²⁰. In another study periodontal ligament space was assessed on CBCT images and PA by previously calibrated and trained dentists, dental assistants and dental students²¹. The significant difference between the observers was not found²¹. The authors pointed out that the observers' calibration and training in CBCT image analysis play a more significant role in CBCT image interpretation than the observers' clinical experience¹⁷.

Experimental studies (*in vitro* and *ex vivo*) which considered the impact of experience in working with CBCT showed high accuracy in FD detection on CBCT images^{12, 22-24}. Three observers with different level of education (PhD student, two radiology faculty members) were assessing the alveolar bone level, craters and FD on CBCT images and PA²². No intra or interobserver variability was found in measurements or classification when the imaging methods were compared²². In the study of Umetsubo et al.¹² initial FDs were detected by two observers with extensive experience in interpreting CBCT scans, who passed CBCT training. Moderate inter and intraobserver agreement could be explained by the fact that in the study a dry mandible was used and trabeculations were wide, only contrasting with air²⁵. Likewise, in another *in vitro* study the impact of different voxel sizes on FD assessment in rat model were evaluated by two dentomaxillofacial radiology specialists and two periodontology specialists and showed strong and excellent intraobserver agreement (0.600 to 0.999) and moderate interobserver agreement (0.366 to 0.589)²³.

The results of Fleiner et al.²⁴ suggested an accurate assessment of bone craters and FD by means of CBCT. In this study, three trained and calibrated observers with different levels of CBCT proficiency (observers with 1, 3 and 6 years of working experience with CBCT devices) and several years of clinical experience assessed circumferential periodontal bone loss, intrabony craters and FD in the human dry cadaver skull and CBCT images²⁴. They concluded that the effect of individual observers' activity on measurement error was not statistically significant²⁴. All clinically detected FI in the examined teeth could be radiologically detected and confirmed by all observers²⁴.

The results of these experimental studies must be interpreted cautiously. The factors that may affect the clarity and accuracy of CBCT images, such as motion artefacts and artefacts due to the presence of metal structures ("scatter", "streaking artifacts", "beam hardening") were avoided in these studies²⁶⁻²⁸. Further, it is also important to note that the artificially created defects were more regular in shape, with clearer edges and positioned on the expected sites than those that are formed in the course of periodontitis, which may facilitate their detection on CBCT images².

Since no effort was made to calibrate the observers, the results of these study suggest that the detection of FD is not observer dependent. However, only the presence or absence of FD were assessed on the CBCT images with no attempt to classify the FD. Further studies are indicated to elucidate whether the CBCT proficiency and clinical experience would have an impact on FD classification on CBCT images.

Conclusions

According to the obtained results, it can be assumed that clinical experience and CBCT proficiency do not have an impact on FD detection on CBCT images, if an appropriate training was previously performed.

Acknowledgement This work was supported by the Ministry of Education and Science of the Republic of Serbia (Grant #41008).

Note: XXI BaSS Congress awarded paper for oral presentation

References

1. Matthews DC, Tabesh M. Detection of localized tooth-related factors that predispose to periodontal infections. *Periodontol* 2000, 2004; 34:136-150.
2. Nikolic-Jakoba N, Spin-Neto R, Wenzel A. Cone Beam Computed Tomography for Detection of Intrabony and Furcation Defects: A Systematic Review Based on a Hierarchical Model for Diagnostic Efficacy. *J Periodontol*, 2016; 1-19.
3. Qiao J, Wang S, Duan J, et al. The accuracy of cone-beam computed tomography in assessing maxillary molar furcation involvement. *J Clin Periodontol*, 2014; 41:269-274.
4. Mol A. Imaging methods in periodontology. *Periodontol* 2000, 2004; 34:34-48.
5. Misch KA, Yi ES, Sarment DP. Accuracy of cone beam computed tomography for periodontal defect measurements. *J Periodontol*, 2006; 77:1261-1266.
6. Mol A, Balasundaram A. In vitro cone beam computed tomography imaging of periodontal bone. *Dentomaxillofac Radiol*, 2008; 37:319-324.
7. Schulze D, Heiland M, Thurmann H, Adam G. Radiation exposure during midfacial imaging using 4- and 16-slice computed tomography, cone beam computed tomography systems and conventional radiography. *Dentomaxillofac Radiol*, 2004; 33:83-86.
8. Vandenberghe B, Jacobs R, Yang J. Diagnostic validity (or acuity) of 2D CCD versus 3D CBCT-images for assessing periodontal breakdown. *Oral Surg Oral Med Oral Pathol Oral Radiol Endod*, 2007; 104:395-401.
9. Braun X, Ritter L, Jervoe-Storm PM, Frentzen M. Diagnostic accuracy of CBCT for periodontal lesions. *Clin Oral Investig*, 2014; 18:1229-1236.

10. Walter C, Weiger R, Zitzmann NU. Accuracy of three-dimensional imaging in assessing maxillary molar furcation involvement. *J Clin Periodontol*, 2010; 37:436-441.
11. Walter C, Kaner D, Berndt DC, Weiger R, Zitzmann NU. Three-dimensional imaging as a pre-operative tool in decision making for furcation surgery. *J Clin Periodontol*, 2009; 36:250-257.
12. Umetsubo OS, Gaia BF, Costa FF, Cavalcanti MGP. Detection of simulated incipient furcation involvement by CBCT: an in vitro study using pig mandibles. *Braz Oral Res*, 2012; 26:341-347.
13. Armitage GC. Periodontal diagnoses and classification of periodontal diseases. *Periodontol 2000*, 2004; 34:9-21.
14. Cimbaljevic MM, Spin-Neto RR, Miletic VJ, Jankovic SM, Aleksic ZM, Nikolic-Jakoba NS. Clinical and CBCT-based diagnosis of furcation involvement in patients with severe periodontitis. *Quintessence Int*, 2015; 46:863-870.
15. Takei HH. & Carranza FA. The surgical Phase of therapy. In: Newman MG, Takei HH, Klokkevold PP, Carranza AF (eds). *Carranza's Clinical Periodontology*, 10th edn. St. Louis, MO: Saunders, Missouri, 2006, pp 881-886.
16. Landis JR, Koch GG. The measurement of observer agreement for categorical data. *Biometrics*, 1977; 33:159-174.
17. Guo YJ, Ge ZP, Ma RH, Hou JX, Li G. A six-site method for the evaluation of periodontal bone loss in cone-beam CT images. *Dentomaxillofac Radiol*, 2016; 45:20150265.
18. Li F, Jia PY, Ouyang XY. Comparison of Measurements on Cone Beam Computed Tomography for Periodontal Intra-bony Defect with Intra-surgical Measurements. *Chin J Dent Res*, 2015; 18:171-176.
19. Grimard BA, Hoidal MJ, Mills MP, Mellonig JT, Nummikoski PV, Mealey BL. Comparison of clinical, periapical radiograph, and cone-beam volume tomography measurement techniques for assessing bone level changes following regenerative periodontal therapy. *J Periodontol*, 2009; 80:48-55.
20. de Faria Vasconcelos K, Evangelista KM, Rodrigues CD, Estrela C, de Sousa TO, Silva MA. Detection of periodontal bone loss using cone beam CT and intraoral radiography. *Dentomaxillofac Radiol*, 2012; 41:64-69.
21. Özmeric N, Kostjoutchenko I, Hägler G, Frentzen M, Jervøe-Storm P-M. Cone-beam computed tomography in assessment of periodontal ligament space: in vitro study on artificial tooth model. *Clin Oral Investig*, 2008; 12:233-239.
22. Vandenberghe B, Jacobs R, Yang J. Detection of periodontal bone loss using digital intraoral and cone beam computed tomography images: an in vitro assessment of bony and/or infrabony defects. *Dentomaxillofac Radiol*, 2008; 37:252-260.
23. Kamburoğlu K, Ereş G, Akgün C, Yeta EN, Gülen O, Karacaoğlu F. Effect of voxel size on accuracy of cone beam computed tomography-aided assessment of periodontal furcation involvement. *Oral Surg Oral Med Oral Pathol Oral Radiol*, 2015; 120:644-650.
24. Fleiner J, Hannig C, Schulze D, Stricker A, Jacobs R. Digital method for quantification of circumferential periodontal bone level using cone beam CT. *Clin Oral Investig*, 2012; 17:389-396.
25. Pinsky HM, Dyda S, Pinsky RW, Misch KA, Sarment DP. Accuracy of three-dimensional measurements using cone-beam CT. *Dentomaxillofac Radiol*, 2006; 35:410-416.
26. Spin-Neto R, Mudrak J, Matzen LH, Christensen J, Gottfredsen E, Wenzel A. Cone beam CT image artefacts related to head motion simulated by a robot skull: visual characteristics and impact on image quality. *Dentomaxillofac Radiol*, 2013; 42:32310645.
27. Mora MA, Mol A, Tyndall DA, Rivera EM. In vitro assessment of local computed tomography for the detection of longitudinal tooth fractures. *Oral Surg Oral Med Oral Pathol Oral Radiol Endod*, 2007; 103:825-829.
28. Soğur E, Baksı BG, Gröndahl HG. Imaging of root canal fillings: a comparison of subjective image quality between limited cone-beam CT, storage phosphor and film radiography. *Int Endod J*, 2007; 40:179-185.

Received on September 15, 2016.

Revised on October 1, 2016.

Accepted on October 2, 2016.

Corresponding author:

Milena Cimbaljevic, PhD
 School of Dental Medicine, Department of Periodontology
 University of Belgrade
 Dr Subotica 8, Belgrade, Serbia
 E-mail: milenacimbaljevic@gmail.com
 Fax: +381 113065463